



PATIENT

Betsy Lee

PRESENTING CLINICAL SIGNS

History: Was seen on 03/18/22 for vomiting. Diagnosed with esophagitis and chronic gastritis.
-Abnormal lab results: Low platelets and **high ProBNP/T4** levels.

SPECIES

Feline

BREED

DSH

ECHOCARDIOGRAM FINDINGS

2D, m-mode, color flow and doppler imaging is available. The left ventricular wall is normal in dimension. There is a mildly hyperechoic endocardium consistent with fibrosis. The LV is mildly dilated with depressed myocardial function. The papillary muscles are mildly remodeled. The left atrium is severely dilated and bulbous in appearance. The right atrium is mildly increased in size. The right ventricle appears normal. The mitral valve is normal in structure and mobility. No MR or TR. Blood flow through both the LVOT and RVOT is normal in velocity. No pleural or pericardial effusion seen. No obvious cardiac tumors.

SEX

Female Spayed

CARDIAC CHART

AGE

11 years

WEIGHT

12.5lbs

INTERPRETED BY

Maggie Machen Lamy,
DVM, DACVIM
(Cardiology)

FELINE CARDIAC PARAMETERS	BODY WEIGHT (kg)	HR (BPM)	IVSd (cm) (Moise, Pipers)	LVIDd (cm) (Moise, Pipers)	LVWd (cm) (Moise, Pipers)	FS (%)	EF (%)
NORMAL PARAMETER	-----	150-240	0.35-0.55	<2 (mean 1.5)	3.5-0.55	35-67	80-100
PATIENT	5.7	180	0.47	1.9	0.40	33	60
FELINE CARDIAC PARAMETERS	LA/AO (Boon)	LA/AO HEART BASE (Swe) (Abbott)	LA 2D short axis Base view (cm) (Abbott)		LVOT VEL (m/s)	RVOT VEL (m/s)	E max (m/s)
NORMAL	<1.5	<1.3	<1.2		<1.6	<1.3	<0.9
PATIENT	1.8	2.0	2.0		0.7	1.0	NM

**Note: All measurements based upon multi-modal images and methods. An average value is reported.
Adapted from June Boon, Veterinary Echocardiography, 1998
Abbott J & MacLean H JVIM 2006;20: 111-119, Moise et al. Am J Vet Res 47:1476, 1986. Pipers et al. Am J Vet Res 40:882, 1979.*

IMAGING PERFORMED BY

Sarah Pender, CVT

INTERPRETATION OF THE FINDINGS & FURTHER RECOMMENDATIONS

The finding of severe LA dilation in the face of essentially normal LV wall thickness with systolic dysfunction is most consistent with unclassified/restrictive cardiomyopathy (R/UCM), however some prior infectious or inflammatory insult to the myocardium cannot be definitively ruled out. There is normal wall thickness, ruling out typical hypertrophic disease. Echocardiography will be helpful to confirm the diagnosis and assess for progression.

HOSPITAL NAME

SVS Imaging QC

Regardless of categorical classification, the finding of severe left atrial dilation is highly concerning as there is high risk for clinical decompensation in the near future, and lifelong medications are warranted as below including low dose diuretic therapy and off-label Pimobendan. The mean survival time for cats once CHF develops is 8-12 months, however most are able to maintain a good quality of life on medications. There will always remain risk for progression to CHF and development of blood clots in the future. Monitoring of sleeping breathing rates at home is recommended as the best way to screen for CHF at home.

REFERRING VET

Dr. Narske

INVOICE

23553

DATE

4/11/22

Elective anesthesia, fluid or steroid therapy is not advised.

**PATIENT**

Betsy Lee

SPECIES

Feline

BREED

DSH

SEX

Female Spayed

AGE

11 years

WEIGHT

12.5lbs

INTERPRETED BYMaggie Machen Lamy,
DVM, DACVIM
(Cardiology)**IMAGING PERFORMED BY**

Sarah Pender, CVT

HOSPITAL NAME

SVS Imaging QC

REFERRING VET

Dr. Narske

INVOICE

23553

DATE

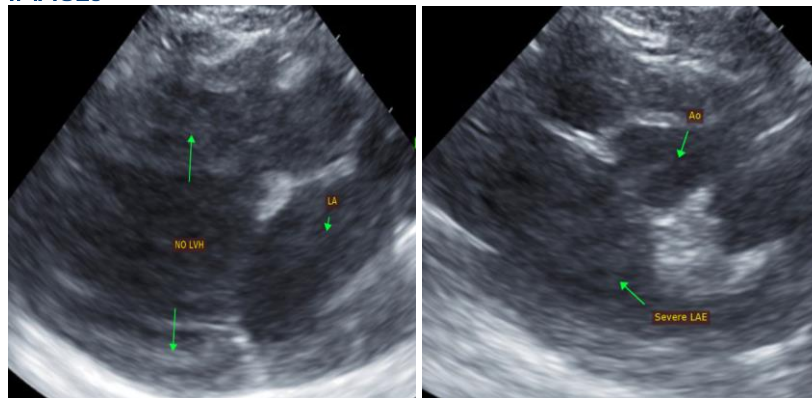
4/11/22

PLAN

Institute diuretic Lasix 1mg/kg PO q12h. Institute blood thinner Clopidogrel (Plavix) 75mg tablets; give ¼ tab orally once daily (NOTE: this medication is very bitter on the cut edges). Institute Pimobendan 1.25mg PO q12h. *Note: If patient is difficult to medicate, Pimobendan and Plavix would be most important.

Recheck renal values and BP in 10-14 days to ensure tolerance of medications, then every 4-6 months lifelong. If BP is >130mmHg and patient is easily medicated, institute ACE-I 0.5mg/kg PO q12h.

A recheck echocardiogram is recommended in 6 months to assess progression.

IMAGES

The information and recommendations provided are based on the images presented by the referring veterinarian. No evaluation can be communicated regarding pathology that was not visible in the image/video clips provided.

Thank you for this referral. If the clinical or image interpretation does not parallel your findings or if I can be of any further assistance, please contact me.

Maggie Machen Lamy, DVM
Diplomate of the American College of Veterinary Internal Medicine (Cardiology)
info@sonopath.com